



DENTAL RATIO
Dental Implant Systems

AUTHOR



Dr. Georg Bach¹

Consultant Dentist for Oral Surgery,
Implant Dentistry Specialist of the
DGZI and BDIZ-ED

¹ FZA Oral Surgery
Rathausgasse 36
79098 Freiburg | Germany

OKTAGON®
BONE LEVEL
IMPLANTS



Closure of an anterior maxillary gap with a crown on an OKTAGON® BONE LEVEL implant

INTRODUCTION

The anterior maxillary area is usually the most challenging area for implant treatment in combination with a restoration. The current case describes the closure of an anterior maxillary gap with an OKTAGON® BONE LEVEL BL RC (Regular Connect) implant and, following osseointegration, an implant-supported screw-retained crown.

DIAGNOSTICS & THERAPY

Medical history & expectation

The consequence of a typical cause of anterior trauma during adolescence was the eventual loss of the lateral right maxillary incisor. After a root filling and subsequent repeated resection, tooth 12 ultimately had to be extracted because it caused persistent problems.

The aim of the subsequent gap closure was an aesthetically appealing result using a minimally invasive procedure that protected the undamaged adjacent teeth 13 and 11.

After almost two decades of treatment of tooth 12, which had been initially restored, then had undergone root canal treatment and was resected twice over the years following anterior trauma during adolescence, the 51-year-old patient presented with progressive and persistent symptoms.

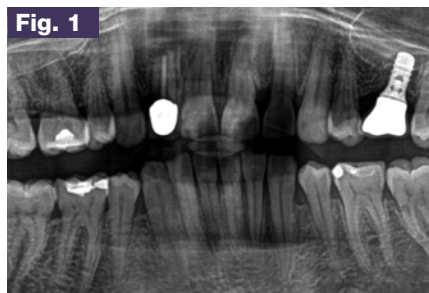


Fig. 1
Tooth 12, not worth preserving

After evaluating the clinical (fistula) and radiological findings (Fig. 1), tooth 12 was classified as not worth preserving.

This corresponded to the patient's understanding, who did not want any further attempts made to preserve the tooth.

As options for treating the prospective gap situation in the prosthetically challenging anterior area, a bridge restoration and an implant supported restoration were possibilities that were discussed with the patient.

Several years prior she had already been referred to our clinic for the treatment of a missing tooth in the left half of the maxilla.

An OKTAGON® TISSUE LEVEL WP (Wide Platform) implant was inserted at the time and later restored with a cemented crown.

Based on her good experiences with an implant restoration, the patient quickly opted for another implantation; in addition, the option of preserving the adjacent teeth with this treatment mode was a major advantage.

PLANNING

The procedure for the implant-supported restoration was discussed in detail with the patient to prevent the risk of resorption of the alveolar bone after removal of the non-preservable tooth 12, especially as the tooth had also been subjected to several injurious incidents in the past (access twice for a resection/persistent inflammations on the root tip of the anterior tooth). The decision was thus made to perform delayed immediate implant placement.

IMPLANT PLACEMENT

Exactly four weeks after gentle extraction of tooth 12, a control X-ray was taken (Fig. 2). An OKTAGON® BL RC implant was inserted in region 12 (Fig. 3). The procedure and the postoperative phase passed smoothly and without problems.

8 weeks after placement of the implant in region 12, the surgical site was re-entered and a healing abutment was placed. Ten days after the re-entering the clinical findings in the anterior maxilla showed no signs of irritation (Fig. 4), enabling an open impression to be taken with a custom tray and the crown to be fabricated (Fig. 5, 6).

To counter the issue of inflammation caused by any cement residue, a screw retained crown was fabricated and fitted (Fig. 7). During the insertion of the screw retained crown, a discrete area of poor blood supply to the peri-implant soft tissue was noticed despite prior widening of the peri-implant soft tissue cuff using a healing abutment.

Fourteen days later the retention screw was removed and the oral opening was closed with a plastic filling. The peri-implant soft tissue situation appeared normal and the aesthetic result is highly satisfying (Fig. 8).

SUMMARY

Thanks to a combination treatment comprising delayed immediate implant placement after gentle extraction of the non-preservable tooth 12, a highly satisfying aesthetic outcome that preserved the adjacent teeth 13 and 11 was achieved.

DENTAL TECHNOLOGY

Dental-Technik Christian Müller
Carl-Kistner-Str. 21
79115 Freiburg i. Brsg. | Germany

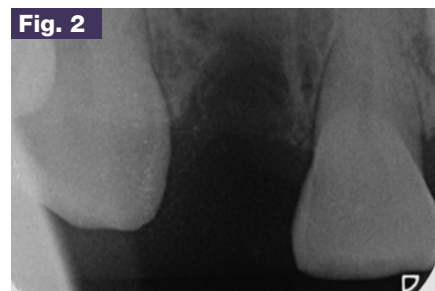


Fig. 2 Interdigital space in region 12 in clinical view

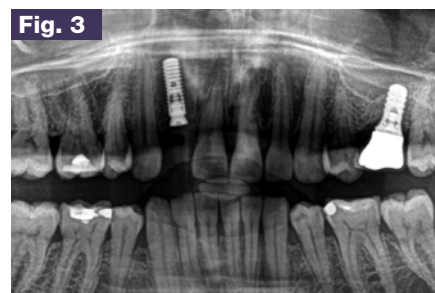

Fig. 3 Control X-ray after insertion of OKTAGON® BL RC Ø 4.1 mm, L 12 mm

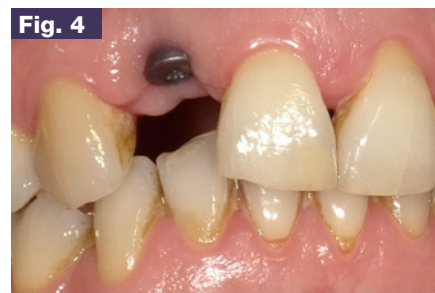

Fig. 4 Situation with healing abutment after healing (2 months after implantation)

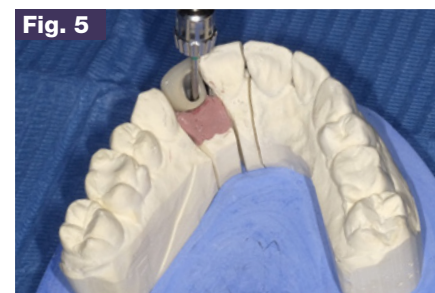

Fig. 5 Screwing in crown 12 on the model

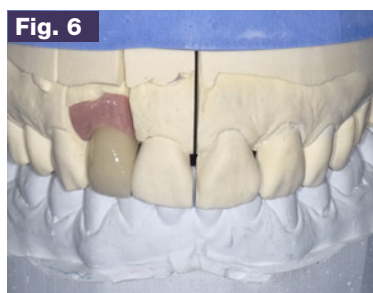


Fig. 6 Anterior view of crown 12 in the model

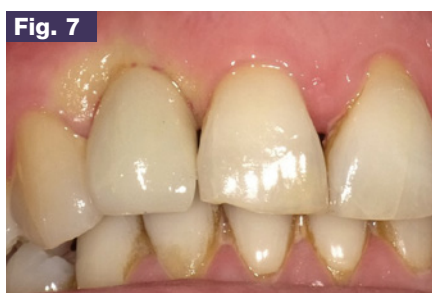

Fig. 7 Postoperative view – immediately after inserting the screw retained crown 12

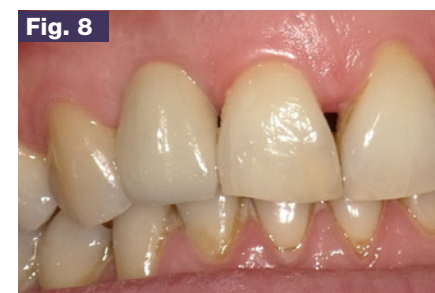

Fig. 8 Final result – 14 days after insertion